


The necessity of anterior transposition of the ulnar nerve in patients receiving corrective osteotomy for cubitus valgus deformity with tardy ulnar nerve palsy: A prospective comparative observational study

Saswat Samant ¹, Ashok Kumar Gachhayat ¹, Sumanyu Kumar Tripathy ¹, Saurav Narayan Nanda ^{1*}, Mac Anson ², Tanmoy Mohanty ³

¹ Assistant Professor, Department of Orthopedics, Kalinga Institute of Medical Sciences, Bhubaneswar, Odisha, India

² Junior Resident, Department of Orthopedics, Kalinga Institute of Medical Sciences, Bhubaneswar, Odisha, India

³ Professor, Department of Orthopedics, Kalinga Institute of Medical Sciences, Bhubaneswar, Odisha, India

* Corresponding author: Saurav Narayan Nanda. Flat No-K1, Rajvatika Appartment, Patia, Bhubaneswar, Odisha, India-751024

Email: saurav.scb@gmail.com

Received: 3 July 2023 Revised: 20 October 2023 Accepted: 26 October 2023 e-Published: 1 January 2024

Abstract

Background: Cubitus valgus deformity is a condition that is often treated with supracondylar corrective osteotomy. Meanwhile, tardy ulnar nerve palsy requires an anterior transposition of the ulnar nerve. This is the most common and preferred procedure. However, there is a lack of research on using a combined approach to deal with both cubitus valgus deformity and tardy ulnar nerve palsy.

Objectives: The purpose of this study was to establish if anterior transposition of the ulnar nerve is necessary in patients with medial closed-wedge osteotomy for cubitus valgus deformity with tardy ulnar nerve palsy.

Methods: This cross-sectional study involved two groups of patients. In the first group, a closed wedge osteotomy was performed without nerve transposition. In the second group, a closed wedged osteotomy was performed with anterior transposition of the ulnar nerve.

Results: The two-point discrimination test was conducted on two groups of patients, group 1 and group 2, both before and after surgery. The mean pre-operative two-point discrimination for group 1 was 5.6, which improved to 3.8 post-operatively. Similarly, the mean pre-operative two-point discrimination for group 2 was 7.5, which improved to 4.0 post-operatively. The mean Disabilities of the Arm, Shoulder and Hand (DASH) score for both groups improved significantly after surgery. For group 1, it improved from 28.8 (pre-operative) to 15.6 (post-operative). For group 2, it improved from 32.5 (pre-operative) to 16.2 (post-operative). The mean Humerus Elbow Wrist (HEW) angle, which is a measure of joint deformity correction, was also improved in both groups after surgery. For group 1, it improved from 35.8 (pre-operative) to 11.4 (post-operative), and for group 2, it improved from 37.2 (pre-operative) to 12.0 (post-operative). The range of motion (ROM) angle was also measured before and after surgery. The mean pre-operative ROM angle was 115 for group 1 and 112.5 for group 2. The mean post-operative ROM angle was 119 for group 1 and 117.5 for group 2. Overall, the functional outcome and deformity correction were excellent in all patients in both groups.

Conclusion: It has been found that treating cubitus valgus deformity with a medial closed wedge osteotomy relieves tension on the tethered ulnar nerve. There seems to be no need for anterior transposition of the ulnar nerve to recover from tardy ulnar nerve palsy. Additionally, there is very little chance of an accidental nerve injury during the procedure.

Keywords: Cubitus valgus, Ulnar nerve palsy, Anterior transposition, Osteotomy.

Introduction

Fractures of the distal humerus that involve the lateral condyle are common in children. These fractures are classified as intraarticular, necessitating immediate care to restore the articular congruity to achieve a favorable

functional outcome.¹ Failure to properly reduce the fracture can lead to a condition called cubitus valgus deformity, which is a common outcome of non-union or malunion.²⁻⁴

The cubitus valgus deformity can cause pain, instability,

and a limited range of motion in the elbow. It can also cause tardy ulnar nerve palsy, the severity of which is determined by the ulnar nerve's involvement and the preoperative cubitus valgus deformity.¹ Studies have shown that the severity of tardy ulnar nerve palsy is directly related to the severity of the initial deformity.⁵⁻⁷

Numerous techniques have been mentioned in the medical literature for treating tardy ulnar nerve palsy. Out of all the procedures, the most common and preferred one is the anterior transposition of the ulnar nerve.^{8,9} If the individual's carrying angle exceeds 20 degrees, a supracondylar corrective osteotomy is typically suggested in individuals with isolated cubitus valgus deformity who do not have neurological symptoms.^{10,11} However, there is limited literature available on a combined approach to managing both the cubitus valgus deformity and tardy ulnar nerve palsy.¹²

Objectives

We conducted research at a tertiary care facility in eastern India to determine the requirement for anterior transposition of the ulnar nerve in patients with cubitus valgus deformity and tardy ulnar nerve palsy who were having a medial closed wedge osteotomy.

Methods

The Kalinga Institute of Medical Sciences' institutional review board authorized the prospective study, which was performed between June 2016 and June 2020. The approval number given was ECR/20201509/Inst/OR/2020. Out of 20 patients, only 9 (5 male patients) were selected based on strict inclusion and exclusion criteria. The research comprised individuals with a cubitus valgus deformity of more than 20 degrees of carrying angle, a history of trauma that resulted in non-union or malunion of the lateral condyle of the humerus, and a history of tardy ulnar nerve palsy. However, patients with bilateral deformity, congenital deformity, and uncorrelated clinic-radiological and electro-physiological studies were excluded from the study. Computer-generated randomization was used, and the nine patients were placed

into two groups. Closed wedge osteotomy without nerve transposition was performed on the patients belonging to the 1st group, while closed wedge osteotomy with anterior transposition of the ulnar nerve was performed on those in the 2nd group.

In Group 1, there are three male and two female patients with an mean age of 27.8 years (range: 23–37 years). Four of the five patients in Group 1 had issues with their right side. The mean time from fracture to the operative procedure was 15.0 years (range: 13–17 years). The mean duration of symptoms was 7.0 months (range: 4–11 months). All patients underwent an electrodiagnostic test. The mean nerve conduction velocity of the sensory nerve of the affected side was 49.5 and the unaffected side was 62.1 (range: 44.7/57.3-54.2/68.8), while the motor nerve was 49.0 and 63.1 (range: 44.3/61.7-54.1/65.1), respectively.

Group 2 was comprised of two male and two female patients, with a mean age of 29.0 years (range: 22–33 years). Three patients had fractures on the right side, while one had them on the left. The mean time between the fracture and operative procedure was 15.0 years (range: 11–18 years), and the mean duration of symptoms was 7.2 months (range: 3–13 months). The mean nerve conduction velocity of the sensory nerve on the affected side was 49.2, while on the unaffected side, it was 64.0 (range: 45.6/59.3-58.4/70.0). As for the motor nerve, the mean velocity on the affected side was 42.5, and on the unaffected side, it was 62.7 (range: 29.7/55.4-53.5/68.2). All patients were followed up for a minimum of 12 months (range: 31.5–54.0). Both groups were homogenous and statistically comparable to each other [Table 1].

Before surgery, all patients underwent a thorough clinical examination and radiological investigation. Standard AP and lateral radiographic views were carried out on all patients, and full-length radiographs, including the humerus, elbow, and wrist, were taken with the elbow extended and the forearm supinated. The HEW (Humerus Elbow Wrist) angle of both upper limbs was measured, and the difference in carrying angles was noted for all patients. The CORA (centre of rotational axis) was located, and the osteotomy site was marked.

Table 1. Patients demographic profile

Patient no.	Age (years)/ Sex	Affected side of the limb	Interval from fracture to operation (years)	Duration of symptoms (months)	Follow-up (months)	Nerve conduction velocity (m/sec)	
						Sensory (affected/unaffected)	Motor (affected/unaffected)
1	M/24	R	17	4	54	53.3/57.3	54.1/62.2
2	F/22	R	11	8	51	46.2/59.3	29.7/68.2
3	M/37	L	17	11	45	44.7/62.8	52.3/62.7
4	F/30	R	15	3	33	58.4/ 70.0	50.1/63.6
5	F/26	R	14	10	28	54.2/68.8	44.5/ 65.1
6	M/31	R	16	5	23	45.6/60.3	36.8/55.4
7	F/29	R	13	4	22	46.8/59.8	44.3/ 61.7
8	M/33	L	18	13	16	50.4/ 66.4	53.5/63.6
9	M/23	R	14	6	12	48.5/ 61.9	49.8/63.6
Mean	5M:4F/ 28.33	7R/2L	15	7.11	31.55	49.78/62.95	46.12/62.9

All patients underwent a surgical procedure while under general anesthesia, positioned on their side with a tourniquet applied. The ulnar nerve was identified and protected through a posterior midline approach. To expose the distal part of the humerus, the tricep was split in the middle. A longitudinal incision was made in the periosteum, and subperiosteal dissection was performed. The osteotomy site was marked using a fluoroscope, and two 1.8mm k wires were inserted into both the proximal and distal osteotomy sites at the desired angle.

After confirming the position of the wires, multiple drill holes were made along the osteotomy site. The osteotomy was completed using a 0.25-inch osteotome while keeping the lateral hinge intact. The osteotomy site was then closed and temporarily held together with K-wires. Finally, the site was fixed using a 3.5-mm anatomical distal humerus medial plate. In group 1 patients, no nerve transposition was performed, while in group 2 patients, anterior transposition of the ulnar nerve was carried out in the subcutaneous plane after raising a muscle fascia. The wound was closed in layers, and the limb was splinted at a 90-degree angle for two weeks. Gentle movements were allowed to achieve full range of motion after that.

Patients who underwent surgery were monitored at specific intervals, including two weeks, six weeks, three months, six months, one year, and annually. Radiographs

were repeated at six weeks and six months to track the progress of the healing process. The radiological union and HEW angle were estimated from the radiological views. After three months of surgery, the Disabilities of the Arm, Shoulder and Hand (DASH) survey was conducted on all patients, and the DASH score was calculated to assess their condition.¹³

The score ranges from 0 to 100, and a higher score indicates less disability. The active range of movement was calculated three months after the operation and compared with the preoperative value. Static longitudinal 2-point discrimination was checked in the little finger of all patients at the three-month post-operative period and compared with the preoperative value. Neurovascular complications associated with the surgical intervention were also noted for all patients. Outcome measures were classified as excellent, good, or poor, depending on the range of movement and deformity of the affected side. If the valgus angle of the affected side is less than 5 degrees and the range of movement is within 5 degrees compared to the normal side, the outcome is considered excellent.

If the deformity correction is within 5–10 degrees or the range of motion (ROM) is within 5–10 degrees as compared to the normal side, the outcome is considered good. However, if valgus angulation or ROM is more than 10 degrees, the outcome is considered poor.

Statistical analysis

The statistical analysis was carried out using SPSS software version 20.0. The ROM of the elbow, 2-point discrimination, HEW angle, and DASH scores were compared with the preoperative score at the three-month follow-up period using the Wilcoxon signed-rank test. A p-value of less than 0.5 was regarded as statistically significant.

Ethical considerations

The study was conducted in accordance with the Declaration of Helsinki. Institutional Review Board approval was obtained. The present study did not interfere with the process of diagnosis and treatment of patients and all participants signed an informed consent form.

Results

All patients showed excellent results in deformity correction, as depicted in Figure 1.

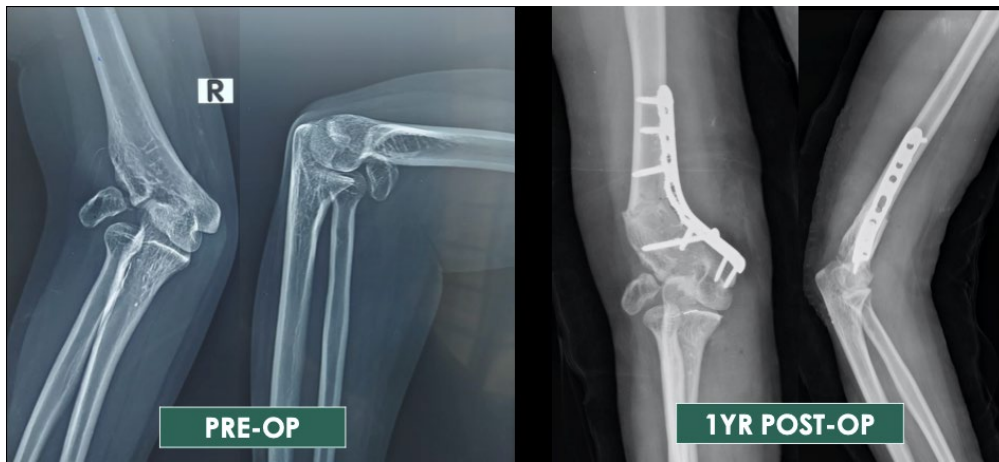


Figure 1. Pre and post- operative radiograph

The study showed an improvement in two-point discrimination for all the patients who underwent surgery. Group-1 patients had a mean two-point discrimination of 5.6 before the surgery, which improved to 3.8 after the surgery. Group-2 patients had a mean two-point

discrimination of 7.5 before the surgery, which improved to 4.0 after the surgery. The study also found that the mean DASH score improved from 28.8 before the surgery to 15.6 after the surgery for group 1 and from 32.5 before the surgery to 16.2 after the surgery for group 2 [Figure 2].

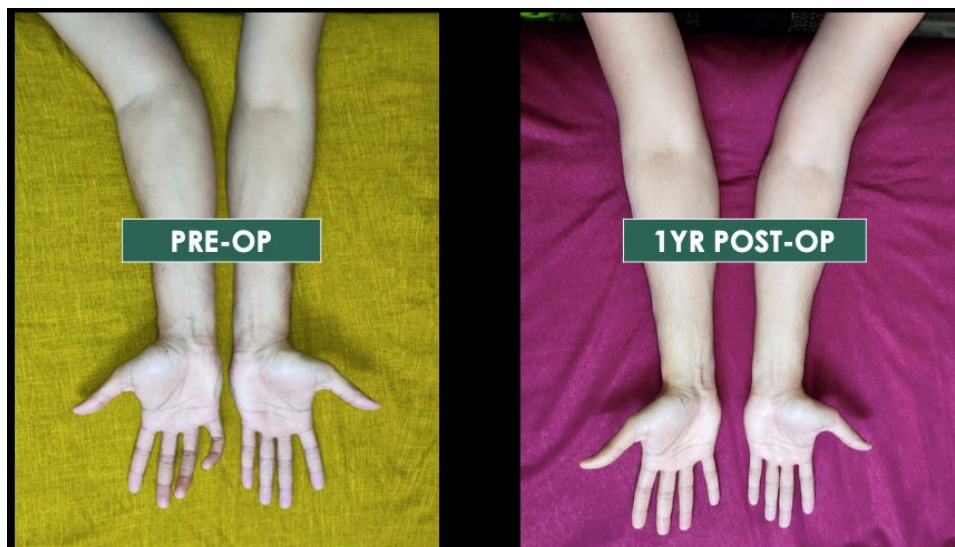


Figure 2. Pre and post- operative clinical image

The mean HEW angle showed improvement in both group 1 and group 2. Group 1 had an improvement from 35.8 (preoperative) to 11.4 (postoperative), while group 2 improved from 37.2 (preoperative) to 12 (postoperative). The mean preoperative ROM angle was 115 for group 1 and 112.5 for group 2. After surgery, the mean post-

operative ROM angle was 119 for group 1 and 117.5 for group 2. Results from two-point discrimination, DASH score, HEW angle, and ROM were compared between the two groups and found to be insignificant with a p-value of less than 0.05, as shown in Table 2. Deformity correction was excellent in all cases.

Table 2. Post-operative outcome comparison with pre-operative value

Patient no.	2-point discrimination		DASH		Normal	HEW angle (°)		ROM angle (°)		Result of deformity correction
	Pre-op	Post-op	Pre-op	Post-op		Pre-op	Post-op	Pre-op	Post-op	
Group-1										
1	3	2	43	10	10	37	13	115	125	Excellent
3	4	3	18	17	16	38	14	130	130	Excellent
5	9	4	33	21	10	24	09	100	110	Excellent
7	6	7	18	11	11	46	10	120	120	Excellent
9	6	3	32	19	15	34	11	110	110	Excellent
Group-2										
2	7	4	44	18	15	34	14	115	120	Excellent
4	8	5	20	13	11	35	10	110	110	Excellent
6	5	3	23	18	13	43	12	125	130	Excellent
8	10	4	43	16	10	37	12	100	110	Excellent

ROM: Range of motion; HEW: Humerus Elbow Wrist; DASH: Disabilities of the Arm, Shoulder and Hand.

Discussion

The medical literature is divided on whether a surgical procedure called "anterior transposition of the ulnar nerve" should be combined with another procedure called "supracondylar humeral osteotomy" to treat patients suffering from a condition known as "cubitus valgus deformity" accompanied by "tardy ulnar nerve palsy." In this study, we analyzed the outcome of these two procedures, performed separately, on two different sets of patients and followed up on them for at least one year. Our findings indicate that there is no significant difference in the functional outcomes observed in the two groups. Furthermore, all patients experienced a successful correction of their deformity without any significant loss of range of motion.

We performed a medial closed wedged osteotomy on all of our patients. Patients with a carrying angle of more than 20 degrees were indicated for distal humeral osteotomy.^{10,11} The mean pre-operative HEW angle was 35.8 degrees in group 1 and 37.2 degrees in group 2. While

medial closed wedged osteotomy is a simple procedure, there is a possibility of decreased range of motion after surgery.¹²⁻¹⁴

In our study, there was no significant lack of ROM after surgery. The mean preoperative ROM angle was 115 degrees for group 1 and 112.5 degrees for group 2. The mean post-operative ROM angle was 119 degrees for group 1 and 117.5 degrees for group 2. One drawback of the medial closed wedged osteotomy was the possibility of the medial condyle becoming more prominent.¹⁵ However, none of our patients reported any implant prominence. The step-cut osteotomy was another surgical procedure with excellent clinical results, but it can be challenging to control the rotation of the fragments once the osteotomy is completed.^{15,16}

The dome osteotomy is a surgical procedure that corrects deformities. It helps maintain the center of rotation of the distal humeral fragment in the midline without creating any medial prominence.^{11,16} However, unlike the medial closed wedge osteotomy, it does not decompress the

stretched-out ulnar nerve. Therefore, if we choose the dome osteotomy procedure, we may need to add an anterior transposition procedure to decompress the ulnar nerve.

The recovery from ulnar palsy that occurs after surgery depends on the severity of the nerve injury before the operation and the extent of the deformity. Most medical experts recommend the use of anterior transposition of the ulnar nerve, with or without correcting the cubitus valgus deformity.^{9,12,17} In our case series, we corrected the deformity in all cases, with or without anterior transposition of the ulnar nerve.

According to some authors, there is no improvement in ulnar nerve symptoms after anterior transposition of the ulnar nerve without osteotomy.^{9,12} This is because there is a possibility of accidental injury to the ulnar nerve while performing the anterior transposition of the nerve, as stated in the literature.¹⁸ After undergoing a medial closed-wedged osteotomy, the stretched-out nerve becomes lax and may not require anterior transposition. In our series, there were no iatrogenic injuries to the nerve. Additionally, all our patients showed signs of recovery in the ulnar nerve after the procedure. Two-point discrimination was improved in all of the patients. The preoperative mean two-point discrimination of group 1 was 5.6 and improved to 3.8 post-operatively. Similarly, the preoperative mean two-point discrimination of group-2 was 7.5 and improved to 4.0 post-operatively. The functional outcome and deformity correction were excellent in all cases.

We need to keep in mind that our study had some limitations. Firstly, the sample size was small, consisting of only 44 patients. However, it is worth noting that, due to the type of injury being studied, most studies in the literature have similarly low sample sizes. Additionally, the compensatory movement of the shoulder may have led to an overestimation of the HEW angle. Despite our efforts to minimize observational variations in the angle calculation, there is still room for error. Lastly, there is currently no scoring system available specifically for elbow injuries, so we had to use the DASH scoring system for upper extremities in our study. The DASH scoring system is not unique to elbow function; hence, the functional

score can be influenced by upper-limb disorders other than the elbow joint. Our research suggests that performing only a medial closed wedge osteotomy is sufficient to release tension in the ulnar nerve. There appears to be no need for an anterior transposition of the ulnar nerve to recover from tardy ulnar nerve palsy. The risk of iatrogenic nerve injury is very low, and this procedure does not affect the range of motion or function of the affected elbow joint. However, a randomized trial with a larger sample size would help to establish a definitive consensus.

Conclusions

A medial closed wedge osteotomy can correct the cubitus valgus deformity and relieve tension on the tethered ulnar nerve without requiring anterior transposition of the ulnar nerve. This approach presents very little risk of iatrogenic nerve injury and does not impact the range of motion or function of the elbow joint on the affected side. As a result, it is an effective treatment option for tardy ulnar nerve palsy.

Acknowledgment

None.

Competing interests

The authors declare that they have no competing interests.

Abbreviations

ROM: Range of motion;

HEW: Humerus Elbow Wrist;

CORA: Centre of rotational axis;

DASH: Disabilities of the Arm, Shoulder and Hand.

Authors' contributions

SS, AKG, SNN were the operating surgeon. Both the data were collected by MA and TM. SKT and SSN wrote up the paper. All authors read and approved the final manuscript. All authors take responsibility for the integrity of the data and the accuracy of the data analysis.

Funding

None.

Role of the funding source

None.

Availability of data and materials

The data used in this study are available from the corresponding author on request.

Ethics approval and consent to participate

The study was conducted in accordance with the Declaration of Helsinki. Institutional Review Board approval was obtained. The present study did not interfere with the process of diagnosis and treatment of patients and all participants signed an informed consent form.

Consent for publication

By submitting this document, the authors declare their consent for the final accepted version of the manuscript to be considered for publication.

References

- Anuar-Ramdhan IM, Remli R, Abdul-Rashid AH, Ibrahim S. Cubitus Valgus with Tardy Ulnar Nerve Palsy- Is Anterior Transposition of the Ulnar Nerve Always Necessary? A Case Report. *Malays Orthop J*. 2020;14:126-129. doi:10.5704/MOJ.2007.010 PMID:32983387 PMCID:PMC7513666
- Gay JR, Love JG. Diagnosis and treatment of tardy paralysis of the ulnar nerve; based on a study of 100 cases. *J Bone Joint Surg Am*. 1947; 29:1087-1097.
- Mc Gowan AJ. The results of transposition of the ulnar nerve for traumatic ulnar neuritis. *J Bone Joint Surg Br*. 1950; 32:293-301. doi:10.1302/0301-620X.32B3.293 PMID:14778847
- Toh S, Tsubo K, Nishikawa S, Inoue S, Nakamura R, Harata S. Long-standing nonunion of fractures of the lateral humeral condyle. *J Bone Joint Surg Am*. 2002;84:593-598. doi:10.2106/00004623-200204000-00013 PMID:11940620
- Barrios C, Ganoza C, de Pablos J, Canadell J. Posttraumatic ulnar neuropathy versus non-traumatic cubital tunnel syndrome: clinical features and response to surgery. *Acta Neurochir*. 1991; 110:44-48. doi:10.1007/BF01402047 PMID:1882718
- Dellon AL. Review of treatment results for ulnar nerve entrapment at the elbow. *J Hand Surg Am*. 1989;14:688-700. doi:10.1016/0363-5023(89)90192-5 PMID:2666496
- Mowlavi A, Andrews K, Lille S, Verhulst S, Zook EG, Milner S. The management of cubital tunnel syndrome: a meta-analysis of clinical studies. *Plast Reconstr Surg*. 2000;106:327-334. doi:10.1097/00006534-200008000-00014 PMID:10946931
- Helfet DL, Kloen P, Anand N, Rosen HS. Open reduction and internal fixation of delayed unions and nonunions of fractures of the distal part of the humerus. *J Bone Joint Surg Am*. 2003; 85:33-40. doi:10.2106/00004623-200301000-00006 PMID:12533569
- Mortazavi SM, Heidari P, Asadollahi S, Farzan M. Severe tardy ulnar nerve palsy caused by traumatic cubitus valgus deformity: functional outcome of subcutaneous anterior transposition. *J Hand Surg Eur Vol*. 2008;33:575-580. doi:10.1177/1753193408092252 PMID:18662958
- Masada K, Kawai H, Kawabata H, Masatomi T, Tsuyuguchi Y, Yamamoto K. Osteosynthesis for old, established non-union of the lateral condyle of the humerus. *J Bone Joint Surg Am*. 1990; 72:32-40. doi:10.2106/00004623-199072010-00006
- Tien YC, Chen JC, Fu YC, Chih TT, Hunag PJ, Wang GJ. Supracondylar dome osteotomy for cubitus valgus deformity associated with a lateral condylar nonunion in children. *J Bone Joint Surg Am*. 2005; 87:1456-1463. doi:10.2106/00004623-200507000-00006
- Kang HJ, Koh IH, Jeong YC, Yoon TH, Choi YR. Efficacy of combined osteotomy and ulnar nerve transposition for cubitus valgus with ulnar nerve palsy in adults. *Clin Orthop Relat Res*. 2013; 471:3244-3250. doi:10.1007/s11999-013-3057-9 PMID:23666592 PMCID:PMC3773147
- Hudak PL, Amadio PC, Bombardier C. Development of an upper extremity outcome measure: the DASH (Disabilities of the Arm, Shoulder and Hand) [corrected]. The Upper Extremity Collaborative Group (UECG). *Am J Ind Med*. 1996;29:602-608. doi:10.1002/(SICI)1097-0274(199606)29:6<602::AID-AJIM4>3.0.CO;2-L
- Jakob R, Fowles JV, Rang M, Kassab MT. Observations concerning fractures of the lateral humeral condyle in children. *J Bone Joint Surg Br*. 1975; 57:430-436. doi:10.1302/0301-620X.57B4.430
- Kim HT, Lee JS, Yoo CI. Management of cubitus varus and valgus. *J Bone Joint Surg Am*. 2005;87:771-780. doi:10.2106/JBJS.D.01870 PMID:15805206
- Hahn SB, Choi YR, Kang HJ. Corrective dome osteotomy for cubitus varus and valgus in adults. *J Shoulder Elbow Surg*. 2009; 18:38-43. doi:10.1016/j.jse.2008.07.013 PMID:19095173
- Tarczynska M, Kolodziej R, Gagala J. Results of operative treatment for ulnar neuropathy in patients with a history of fracture of the lateral part of the humeral condyle in childhood. *Ortop Traumatol Rehabil*. 2007;9:75-81.
- Gokay NS, Bagatur AE. Subcutaneous anterior transposition of the ulnar nerve in cubital tunnel syndrome. *Acta Orthop Traumatol Turc*. 2012;46:243-9. doi:10.3944/AOTT.2012.2836 PMID:22951754

Cite this article as:

Samant S, Gachhayat A, Tripathy S, Nanda S, Anson M, Mohanty T. The necessity of anterior transposition of the ulnar nerve in patients receiving corrective osteotomy for cubitus valgus deformity with tardy ulnar nerve palsy: A prospective comparative observational study. *J Prev Complement Med*. 2024;3(1):22-28. doi:10.22034/NCM.2023.405274.1096